

A 58 years old male was admitted to our hospital due to the right lower chest pain, he was operated ten years ago due to the liver cyst hydatid. The chest computed tomography was demonstrated a cystic lesion in the right lower zone of thorax and diaphragmatic localization (105x80 mm) (Figure 1). He was operated via the right thoracotomy and the cystic lesion was detected between the diaphragm layers (Figure 2a, 2b). Cystotomy and capitonage was done, and he was discharged on the seventh postoperative day uneventfully.

The incidence of diaphragmatic hydatid cysts is very rare. Preoperative diagnosis of complicated hydatid cysts located at the diaphragm is difficult. On the other hand there have been only a few reports of primary diaphragmatic hydatid cysts without being in lung or liver in the literature [1]. In conclusion when the cystic lesion was localized on the lower zone of thorax or upper zone of abdomen, we must suspect diaphragmatic hydatid cyst.

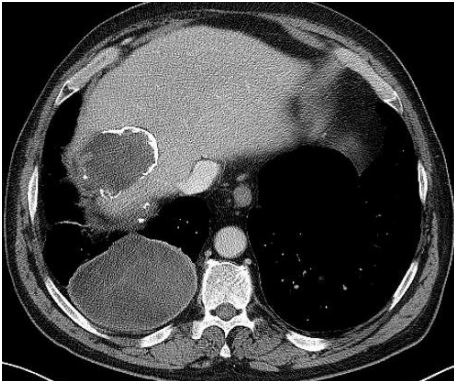


Figure 1. Preoperative chest computed tomography image: Diaphragmatic hydatid cyst and old liver cystic lesion is seen.

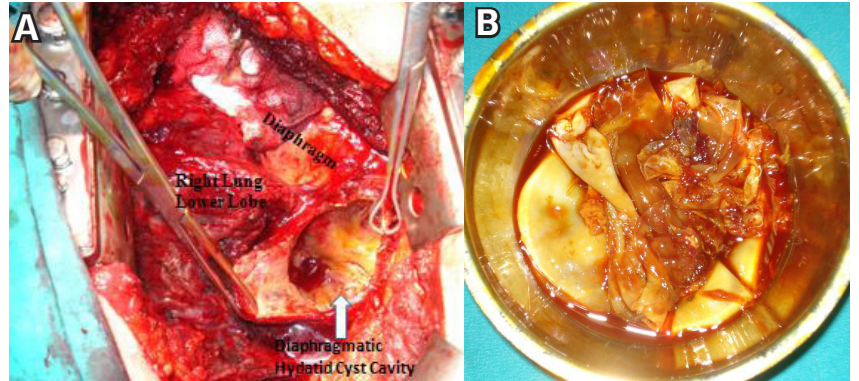


Figure 2. Intraoperative images. Diaphragmatic hydatid cyst(A) and, Germinative membrane(B).

Reference

1. Aydın Y, Özgökçe M, Naldan ME, Türkyılmaz A, Eroğlu A. Diaphragmatic hydatid cyst: report of three cases. Turk Gogus Kalp Dama 2014;22(3):672-5