

Journal of

Clinical and Analytical Medicine

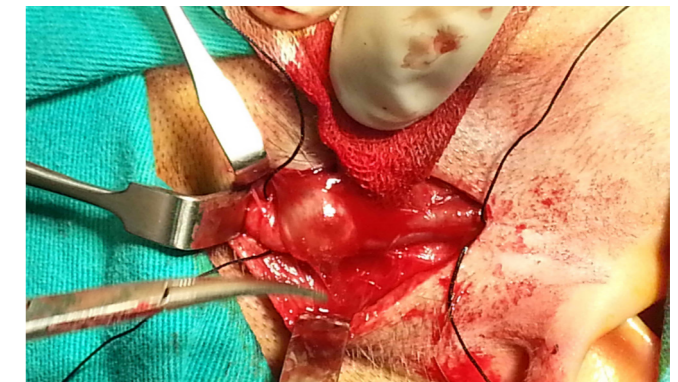
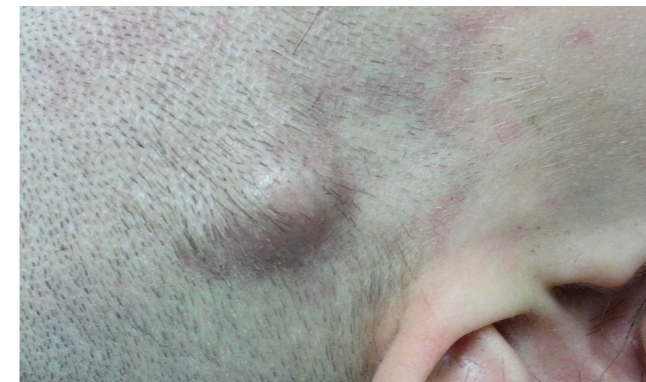Klinik ve Analitik Tıp Dergisi

Vol: 5 Supplement 4 August 2014

Vol: 5 Supplement 4 August 2014

Traumatic Dissecting Aneurysm of Superficial Temporal Artery: A Case Report

Gezici AR, Dagistan Y, Gurel K, Dagistan E, Ozkan N



Contents;

- Left Coronary Artery Originated from Right Sinus of Valsalva: Case Report
- A Rare Cause of Congenital Hypotonia: Walker Warburg Syndrome
- Rhinocerebral Mucormycosis: A Rare Diagnose for Emergency Room; Case Report
- Propylthiouracil Hepatotoxicity Seen with Jaundice and its Treatment by Steroids
- Headache Could Be Finding of Sinus Vein Thrombosis in Behcet's Patients
- Intrauterin Device Migration to the Bladder and Endoscopic Treatment; Case Report
- Giant Retroperitoneal Liposarcoma with Multi-Organ Involvement
- Insulinoma May Present as Epilepsy: A Case Report
- A Case of Chemical Ventriculitis Due to Intraventricular Colistin Treatment
- Coexistence of Schizophrenia and Frontotemporal Dementia: A Case Report
- Titanium Implant Medialization Laryngoplasty Application in the Case of a Silicone and Gore-Tex Extrusion
- Hemoperitoneum From Spontaneous Bleeding of a Uterine Subserous Leiomyoma: A Case Report
- Incomplete McCune-Albright Syndrome: A Case Report

Journal of Clinical and Analytical Medicine / Klinik ve Analitik Tıp Dergisi

