

Journal of

Clinical and Analytical Medicine

Klinik ve Analitik Tıp Dergisi

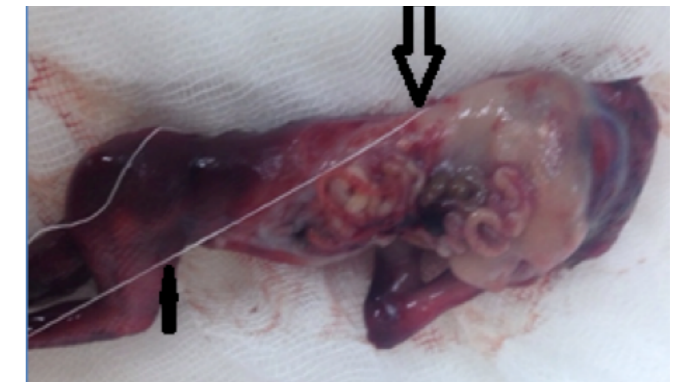
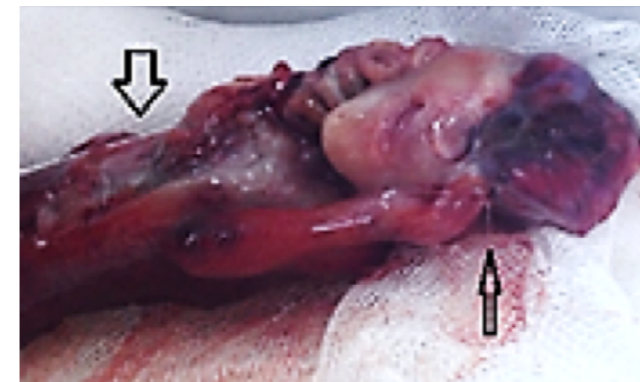
Vol: 6 Supplement 5 October 2015

Vol: 6 Supplement 5 October 2015

Journal of Clinical and Analytical Medicine / Klinik ve Analitik Tıp Dergisi

Amniotic Band Syndrome and a Rarely Seen Subtype: Limb Body Wall Complex

Cırık DA, Altay MM, Kaplan M, Bocutoğlu F, Gelisen O



Contents;

- Skin Prick Test Results of Canakkale Onsekizmart University Faculty of Medicine Dermatology Department
- Clinical, Demographic and Laboratory Features of Patients with Alopecia Areata in Tokat Region
- Evaluation of Urinary Tract Infections Due to Candida Species
- Treatment of Vaginal Agglutination Complicating Chronic Graft-Versus-Host Disease: A Rare Case Report
- Agammaglobulinemia in a Patient with Smith-Lemli-Opitz Syndrome: Case Report
- Is Iatrogenic Cushing's a New Form of Child Neglect?
- Co-Existence of Lymph Node Tuberculosis and Pulmonary Embolism: A Case Report
- Importance of CT Imaging on Spontaneous Rupture of Renal Angiomyolipoma: A Case Report
- Methylenetetrahydrofolate Reductase Polymorphisms at Familial Bladder Cancer: Case Report
- Ruptured Ovarian Dermoid Cyst Mimicking Peritoneal Carcinomatosis: CT and MRI
- A Case of Hydatid Cyst with Localization in Anterior Mediastinum
- A Case Report of Telangiectatic Rosacea Treated with Long Pulsed Nd-YAG Laser

